

# Online Research @ Cardiff

This is an Open Access document downloaded from ORCA, Cardiff University's institutional repository: <http://orca.cf.ac.uk/101141/>

This is the author's version of a work that was submitted to / accepted for publication.

Citation for final published version:

Cassels, Nicola, Wild, John, Margrain, Thomas Hengist, Chong, Victor and Acton, Jennifer 2018. The use of microperimetry in assessing visual function in age-related macular degeneration. Survey of Ophthalmology 63 (1) , pp. 40-55. 10.1016/j.survophthal.2017.05.007 file

Publishers page: <http://dx.doi.org/10.1016/j.survophthal.2017.05.007>  
<<http://dx.doi.org/10.1016/j.survophthal.2017.05.007>>

Please note:

Changes made as a result of publishing processes such as copy-editing, formatting and page numbers may not be reflected in this version. For the definitive version of this publication, please refer to the published source. You are advised to consult the publisher's version if you wish to cite this paper.

This version is being made available in accordance with publisher policies. See <http://orca.cf.ac.uk/policies.html> for usage policies. Copyright and moral rights for publications made available in ORCA are retained by the copyright holders.



## Manuscript Details

<b>Manuscript number</b>	SURVOPH_2017_3
<b>Title</b>	The use of microperimetry in assessing visual function in age-related macular degeneration.
<b>Article type</b>	Review article

### Abstract

Microperimetry is a novel technique for assessing visual function and appears particularly suitable for age-related macular degeneration (AMD). Compared to standard automated perimetry (SAP), microperimetry offers several unique features. It simultaneously images the fundus, incorporates an eye tracking system to correct the stimulus location for fixation loss and identifies any preferred retinal loci. A systematic review of microperimetry in the assessment of visual function in AMD identified 680 articles; of these, 52 met the inclusion criteria. Microperimetry and AMD is discussed in relation to: disease severity; structural imaging outcomes; other measures of visual function; and evaluation of the efficacy of surgical and/ or medical therapies in clinical trials. The evidence for the use of microperimetry in the functional assessment of AMD is encouraging. Disruptions of the ellipsoid zone (EZ) band and retinal pigment epithelium (RPE) are clearly associated with reduced differential light sensitivity (DLS) despite the maintenance of good visual acuity (VA). Reduced DLS is also associated with outer segment thinning and RPE thickening in early AMD and with both a thickening and a thinning of the whole retina in CNV. However, microperimetry lacks the robust diffuse and focal loss age-corrected probability analyses associated with SAP and the technique is currently limited by this omission.

**Keywords** microperimetry, age-related macular degeneration, optical coherence tomography, visual function, systematic review

**Manuscript category** Major Review

**Corresponding Author** John Wild

**Corresponding Author's Institution** Cardiff University

**Order of Authors** Nicola Cassels, John Wild, Tom Margrain, Ngaihang Chong, Jennifer Acton

## Submission Files Included in this PDF

### File Name [File Type]

Letter to the Editor\_220517.docx [Cover Letter]

4-25-17\_microperimetry JA (1).docx [Manuscript File]

To view all the submission files, including those not included in the PDF, click on the manuscript title on your EVISE Homepage, then click 'Download zip file'.

John Gittinger MD  
Editor-in-Chief  
Survey of Ophthalmology

May 22<sup>nd</sup> 2017

**Ref: SURVOPH\_2017\_3**

**Title: The use of microperimetry in assessing visual function in age-related macular degeneration**

Thank you for accepting the above systematic review for publication in Survey of Ophthalmology.

We have incorporated all the editorial corrections with the exception of that in line 5 of the abstract: we wish to retain the adjective 'systematic' before 'review' since it describes the appropriate methodology.

Yours sincerely,

John Wild PhD, DSc

# **The use of microperimetry in assessing visual function in age-related macular degeneration.**

Nicola K Cassels BSc<sup>1</sup>, John M Wild PhD, DSc<sup>1</sup>, Tom H Margrain PhD<sup>1</sup>, Victor Chong MD, FRCOphth<sup>2</sup> and Jennifer H Acton PhD<sup>1</sup>

<sup>1</sup> Cardiff Centre for Vision Sciences, Cardiff University, Cardiff, UK

<sup>2</sup> University of Oxford, Oxford, UK

**Conflicts of interest: none**

Correspondence address:

John M Wild PhD, DSc  
Cardiff Centre for Vision Sciences  
College of Biomedical and Life Sciences  
Cardiff University  
Maindy Road,  
Cardiff,  
CF24 4HQ  
United Kingdom

[WildJM@cardiff.ac.uk](mailto:WildJM@cardiff.ac.uk)

## **Abstract**

Microperimetry is a novel technique for assessing visual function and appears particularly suitable for age-related macular degeneration (AMD). Compared to standard automated perimetry (SAP), microperimetry offers several unique features. It simultaneously images the fundus, incorporates an eye tracking system to correct the stimulus location for fixation loss, and identifies any preferred retinal loci. A systematic review of microperimetry in the assessment of visual function in AMD identified 680 articles. Of these, 52 met the inclusion criteria. We discuss microperimetry and AMD in relation to disease severity, structural imaging outcomes, other measures of visual function, and evaluation of the efficacy of surgical and/ or medical therapies in clinical trials. The evidence for the use of microperimetry in the functional assessment of AMD is encouraging. Disruptions of the ellipsoid zone band and retinal pigment epithelium (RPE) are clearly associated with reduced differential light sensitivity (DLS) despite the maintenance of good visual acuity . Reduced DLS is also associated with outer segment thinning and RPE thickening in early AMD and with both a thickening and a thinning of the whole retina in choroidal neovascularization. Microperimetry, however, lacks the robust diffuse and focal loss age-corrected probability analyses associated with SAP, and the technique is currently limited by this omission.

**Key words:** microperimetry, age-related macular degeneration, optical coherence tomography, visual function, systematic review

## I. Introduction

Age-related macular degeneration (AMD) <sup>1</sup> is the leading cause of blindness in the developed world <sup>66</sup> and accounts for the majority of registerable visual impairment in both the USA and the UK <sup>10,37,54</sup>. Visual acuity (VA) is the most widely used outcome measure in ophthalmic research; however, VA is insufficiently sensitive to detect the early stages of functional loss in AMD <sup>42,50</sup>. Various other tests of visual function, such as dark adaptation <sup>46</sup>, flicker threshold <sup>15</sup> and photostress recovery time <sup>44</sup> are more sensitive than VA in detecting early functional loss in AMD; however, such tests have limited clinical utility because they are time-consuming <sup>44</sup>. There is, therefore, a need for a robust and clinically appropriate technique to assess visual function across the macula that is more indicative than VA.

Microperimetry is similar to standard automated perimetry (SAP) in that it measures the differential light sensitivity (DLS), i.e. the minimum luminance of a white spot stimulus superimposed upon a white background of uniform luminance necessary to perceive the stimulus. Microperimetry, however, is novel in that it uses an eye tracking system to correct the position of the stimulus for any changes in fixation. Such a correction is particularly appropriate in the later stages of macular disease where unsteady fixation and/ or a preferred retinal locus are common. Microperimetry offers the additional benefit of providing a real-time en-face image of the posterior pole. The latter is of value in macular disease as it enables

---

<sup>1</sup> Abbreviations - DLS: Differential light sensitivity, MAIA: Macular Intensity Assessment, SLO: Scanning laser ophthalmoscopy, MS: Mean Sensitivity, TD: Total Deviation, MD: Mean Deviation, nGA: Nascent geographic atrophy, ORT: Outer retinal tubulations, LLD: Low luminance deficit; AREDS: Age-related Eye Disease Study, GA: geographic atrophy, EZ: ellipsoid zone, ELM: external limiting membrane, INL inner nuclear layer; OPL: outer plexiform layer, nGA: nascent geographic atrophy, FAF: fundus autofluorescence, NIR-FAF: near-infrared fundus autofluorescence, anti-VEGF: anti-vascular endothelial growth factor, dB: decibel, mfERG: multifocal electroretinography.

direct comparison between the visual function outcome and the underlying fundus appearance

2.

The concept of microperimetry was initially introduced clinically in 1981<sup>67</sup>. Currently, there are two commercially available microperimeters: the Nidek MP-3 (Nidek Technologies, Padova, Italy) and the Macular Integrity Assessment microperimeter (MAIA, CentreVue, Padova, Italy). These instruments have an improved dynamic range of 34dB (maximum stimulus intensity of 3183 cdm<sup>-2</sup>) for the MP-3 and 36dB (318 cdm<sup>-2</sup>) for the MAIA, compared to 20dB for the two earlier commercially available instruments, the MP-1 (128cdm<sup>-2</sup>) and the Optos optical coherence tomography (OCT) scanning laser ophthalmoscope (SLO) (Optos, Dunfermline, Scotland, UK) (125cdm<sup>-2</sup>). The background luminance for the MAIA is 1.27cdm<sup>-2</sup>; while the MP-3 offers the option of either 1.27cdm<sup>-2</sup> or 10cdm<sup>-2</sup>. The technical specifications of the current and earlier microperimeters are reviewed in detail elsewhere<sup>40</sup>. The eye-tracking systems automatically register the eye position 25 times per second relative either to given anatomic landmarks (MP-3) or to each pixel of the fundal image (MAIA).

Mean Sensitivity (MS) is the most common outcome measure in microperimetry and is defined as the mean of the DLS obtained across all the designated stimulus locations; however, the MS is a summary measure and does not account for the decline in DLS with age. Less common, but more appropriate, outcome measures for microperimetry are the Total Deviation (TD), defined as the difference between the DLS at a given stimulus location and the corresponding age-corrected normal value, and the Mean Deviation (MD), defined as the arithmetic mean of the TD obtained across all the designated stimulus locations. A worsening of visual function is indicated by an increasingly less positive MS and by an increasingly negative TD and MD.

Given that the microperimetry is novel and that the design features appear particularly suitable for assessing visual function in AMD, we undertook a systematic review to evaluate the literature relating to the use of microperimetry for assessing visual function in AMD.

## **II. Results**

The search identified 674 primary articles. Six additional articles were obtained from the references within the primary retrieved articles. The final number of included articles was 52 (Figure 1).

We divided our review into four principle areas that reflected the content of the included articles: evaluation of the efficacy of microperimetry in distinguishing between the various stages of AMD severity (4 articles), the relationship between microperimetry outcomes and structural imaging outcomes (including Spectral Domain Optical Coherence Tomography, SD-OCT) (21 articles), the relationship between microperimetry outcomes and those of other measures of visual function (12 articles), and microperimetry outcomes in the evaluation of the efficacy of medical therapy and/ or surgical intervention in the treatment of AMD (17 articles).

### **A. Quality of evidence**

The quality of each of the 52 included articles is described in Table 1, which is ordered by quality of evidence. The studies were classified as either experimental or observational. Within these two classifications, experimental studies were classified as either randomised control trial (RCT) or as non-randomised design, which will be referred to as quasi-experimental. Observational studies were classified as cross-sectional, case-controlled or case series. None of the included studies were cohort studies. Assessment of the quality of reporting showed



that over half the articles included in this review had limitations relating to the quality of the microperimetry outcome (18 articles) and/ or to the reporting of the SD-OCT methods and analysis (11 articles). The reporting of microperimetry stimulus parameters was also generally poor, particularly in regard to the description of the stimulus program (i.e., the number, the location, and the separation, of the stimuli).

The method of classification of AMD severity varied between the various studies and limited the meaningful comparisons between studies. These comprised the AREDS grading system <sup>7</sup> (7 articles), the Beckman classification <sup>19</sup> (9 articles), the Wisconsin Age-related Maculopathy Grading system <sup>36</sup> (1 article), and the International Classification and Grading system <sup>8</sup> (2 articles). Consequently, the classification method utilised in each study is noted, where appropriate, throughout this review.

Similarly, the difference in the stimulus parameters and also in the dynamic range between the various microperimeters used, hinder direct comparisons of DLS between studies <sup>1</sup>. Microperimetry was undertaken by the Nidek MP1 or MP1-S in 29 of the 52 included articles <sup>3,5,9,12,16,17,23,25,32–35,39,41,43,45,48,49,51,52,55–57,59–63,68</sup> by the Nidek MP3 in 1 <sup>27</sup>, by the MAIA in 13 <sup>4,6,11,65,69–77</sup>, by the Optos Spectral OCT/SLO in 7 <sup>13,20,28–30,38,53</sup> and by the Rodenstock SLO microperimeter in two articles <sup>18,22</sup>. The limited dynamic range of the previously available Optos OCT SLO and Nidek MP-1 microperimeters arising from the lower maximum stimulus luminance results in ceiling and floor effects compared to the MAIA and MP-3 microperimeters <sup>40</sup>. In particular, the presence of a floor effect can result in underestimation of the depth of the field loss. Consequently, the type of microperimeter is specified whenever the perimetric outcome is given in decibels (dB).

## B. Microperimetry and AMD severity

Four of the 52 included articles evaluated the efficacy of microperimetry in distinguishing between the various stages of AMD severity<sup>16,22,65,70</sup>. Microperimetry with the MAIA is able to discriminate between normality and early and intermediate stages of AMD (Age-related Eye Disease Study, AREDS<sup>7</sup>, grades 2 and 3 respectively) when considered both in terms of the group mean MS and of the DLS derived at individual locations<sup>65</sup>. In the largest study of this kind to date, the group of 200 normal individuals exhibited the highest MS (mean 29.8 dB; SD 1.7) while within the group of 200 individuals with AMD, the MS for those with early AMD was larger (mean 24.9 dB; SD 3.9) than for those with intermediate AMD (mean 21.8 dB; SD 5.4-  
-all  $p < 0.001$ )<sup>65</sup>. A comparable, but earlier, study of 30 individuals found a statistically significant worsening of both the group mean MS and the group mean MD for intermediate AMD (AREDS grade 3) compared to normal individuals<sup>16</sup>. For both these studies, the magnitudes of the group mean MS reflected the severity of the structural classification of AMD; however, the magnitudes of the standard deviations associated with the group mean MS indicated overlap between groups. In addition, no criteria for microperimetry were given for the optimal differentiation, on an individual basis, between the AMD severities. The analysis of the DLS at each individual stimulus location enabled a localised assessment of function that was more descriptive of the AMD severity than that provided by the MS<sup>70</sup>.

The reduction in DLS varies with the location and severity of the AMD. Eyes with subfoveal neovascular AMD (nAMD) that exhibit severe (absolute) localised parafoveal abnormality (0 dB, as measured by an early commercially available Rodenstock SLO microperimeter; Rodenstock GmbH, Munich, Germany) manifest a normal foveal DLS, enabling central fixation to be maintained<sup>22</sup>. The likelihood of a dense parafoveal abnormality increases as the duration of self-reported symptoms increases<sup>22</sup>.

In summary, the MS derived by microperimetry is reduced in eyes with AMD and is able to differentiate, on a group mean basis at least, between levels of disease severity <sup>16,65</sup>. The evidence, however, is questionable as to whether microperimetry can correctly classify AMD disease severity. Characterising the reduction in DLS by location, area and depth enables the study of associations with other factors such as disease duration and maintenance of central fixation <sup>22</sup>.

### C. Microperimetry and structural imaging modalities

Twenty of the 52 included articles were concerned with the relationship between visual function and retinal morphology in AMD <sup>3,20,21,27–29,33,34,38,45,51,52,57,59,61,63,73–76</sup>, most of which used SD-OCT. This section discusses microperimetry outcomes in relation to specific retinal layer changes, retinal pseudodrusen, geographic atrophy (GA), and outer retinal tubulations (ORTs).

A typical SD-OCT horizontal line scan of an individual with AMD illustrating the retinal layers evaluated in the various studies is shown in Figure 2. The external limiting membrane (ELM) appears as a hyper-reflective line, by SD-OCT, in the outer retina just above the ellipsoid zone (EZ). The EZ is also visible as a hyper-reflective band, but is not synonymous with a single retinal anatomical feature <sup>64</sup>. The photoreceptor outer segment layer appears below the EZ band and is visible as a hyporeflective line. The retinal pigment epithelium (RPE) layer also appears as a hyper-reflective line that is continuous with Bruch's membrane until disease processes cause their separation.

Reticular pseudodrusen represent a build-up of material below the RPE and, when viewed by SD-OCT, manifest as hyper-reflective triangular shaped deposits located between the RPE and the EZ band (Figure 3) <sup>58,80</sup>. Geographic atrophy (GA) is the late stage of AMD, with loss of retinal structures including the RPE and photoreceptors and the ensuing visibility of the underlying choroidal vessels (Figure 4) <sup>27</sup>. Nascent geographic atrophy (nGA) as defined by Wu and colleagues<sup>73</sup> occurs prior to drusen-associated atrophy and has similar risk factors to GA and can be visualised by SD-OCT, but not by color fundus photography <sup>73</sup>. nGA appears by SD-OCT as a breakdown of the outer plexiform layer (OPL) and inner nuclear layer (INL) accompanied with a wedge-shaped hyporeflective area in the OPL <sup>78</sup>. Finally, ORTs can only be visualised by SD-OCT and appear as a hyper-reflective ring with a hyporeflective center located within the outer nuclear layer (Figure 5).

### *1. Retinal layers*

The relationship between outer retinal layer thickness and DLS in early AMD has been investigated by comparing RPE and OS thicknesses at locations with and without an abnormal DLS (defined as a TD value with a probability of lying within the normal range of  $p \leq 0.05$ ) <sup>3</sup>. The OS layer was thinner at locations with an abnormal TD ( $p < 0.01$ ). The OS layer thickness was also significantly correlated with both MS and MD obtained using the MP-1 microperimeter ( $r = 0.62$  and  $r = 0.63$ , respectively, both  $p < 0.01$ ) <sup>3</sup>. MS worsens with increased thickening of the RPE <sup>3,74,76</sup>. A 10 $\mu\text{m}$  increase in RPE layer thickness is associated with a 0.29 dB worsening of MS ( $p < 0.001$ ) obtained with the MAIA microperimeter <sup>76</sup>.

In eyes with early to intermediate AMD, the MS at locations overlying drusen is statistically significantly worse than that at adjacent locations <sup>28,34</sup>. EZ band disruption is the strongest predictor of DLS at locations with drusen, <sup>28</sup> and the reduction in MS in the presence of EZ

band disruption is worse than that in the presence of drusen alone <sup>34</sup>. Notably, in the former study the stage of AMD was not classified. Individuals exhibiting drusen (excluding nAMD) were included and, therefore, any stage of AMD may have been involved <sup>28</sup>. In early to late atrophic AMD, MS worsens as the EZ band disturbance increases <sup>38,53,74</sup>. In nAMD, a worsening of EZ band disruption and an increase in central retinal thickness are both associated with a reduction in MS ( $r=-0.79$ ;  $p<0.001$  and  $r=-0.51$ ;  $p<0.01$ , respectively) <sup>38,61</sup>. Similarly, in nAMD treated with bevacizumab, MS significantly worsened ( $p<0.01$ ) with increase in EZ band disruption <sup>29</sup>. The presence of nAMD, intra-retinal cysts and a focal/localised absence either of the RPE or of the photoreceptor layer are each associated with an absolute loss of MS ( $<0\text{dB}$ ) obtained with the MP-1 microperimeter <sup>61</sup>. Sub-retinal fluid, intra-retinal fluid, pigment epithelial detachment (PED) and pseudodrusen are each separately associated with relative visual field loss (defined as 1 dB to 8 dB) when measured with the MP-1 microperimeter <sup>61</sup>.

## *2. Reticular pseudodrusen*

The presence of reticular pseudodrusen in early to intermediate AMD (AREDS grade 2, 3 or 4 <sup>7</sup>) is associated with a reduction in MS out to 10° eccentricity <sup>45</sup>. Such an association is absent in a cohort with intermediate stage AMD (Beckman classification <sup>19</sup>) <sup>75</sup>. MS out to 4° eccentricity was associated with reticular pseudodrusen on a univariate basis; however, in a multivariate analysis incorporating age, drusen volume, and pigmentary disturbance, the association was no longer present <sup>75</sup>. One explanation for these findings may simply be the difference in classification systems used for the two studies. In early to intermediate AMD (Beckman classification<sup>19</sup>), both scotopic and mesopic group mean MSs, obtained with a modified MP-1S microperimeter, were reduced in areas of reticular pseudodrusen (mean 12.8dB; SD 3.3 and mean 17.2dB; SD 2.5, respectively) compared to areas without (mean 18.2dB; SD 2.2 and mean 18.4dB; SD 2.5, respectively). The scotopic MS was reduced to a

greater extent than the mesopic MS<sup>59</sup>. These findings suggest that, in the presence of reticular pseudodrusen, rod photoreceptor function is the most affected. It is not clear, however, whether the greater reduction in the scotopic MS was caused by differences in the measurement range resulting from the two different background luminances enabling scotopic and mesopic viewing conditions. Scotopic dysfunction also correlates with outer retinal thickness in eyes with reticular pseudodrusen: a 1µm decrease in thickness corresponded to a 0.96dB reduction in scotopic MS<sup>59</sup>. In another study, the MS was also reduced in the presence of pseudodrusen in atrophy-free areas of eyes with GA<sup>63</sup>.

### 3. *Geographic atrophy*

In GA, MS has been compared between areas with and without either RPE loss and/ or photoreceptor damage<sup>63</sup>. The group mean MS, obtained with the MP-1 microperimeter, was markedly lower in areas of RPE loss (mean 1.84 dB; SD 2.68; p<0.001) and also in areas with photoreceptor damage (mean 6.57 dB; SD 4.13; p<0.001) when compared to areas without<sup>63</sup>. In GA, a thinning or an absence of the RPE, an absence of the external limiting membrane, and a thickening of the EZ boundary are each associated with absolute field loss (0dB) obtained with the MP-1 microperimeter<sup>57</sup>. The group mean MS obtained with the MP-3 microperimeter at the GA boundary is lower (mean 13.7dB; SD 4.7) than the group mean MS in the area surrounding the GA (mean 20.8dB; SD 3.8); however, the latter is lower than that in eyes without GA (mean 23.9dB; SD 2.6) (p<0.001)<sup>27</sup>. Another study utilized en-face OCT to identify GA boundaries at the choroidal and the outer retinal levels. When the MS was better than 10dB, the mean area of GA was larger at the outer retinal level than at the choroidal level; however, the areas were similar when the MS was worse than 10dB<sup>51</sup>.

In areas of nGA, the group mean MS measured by MAIA microperimetry is reduced (mean 20.4 dB; SD 0.8) compared to areas without atrophy (mean 23.8 dB; SD 0.7,  $p < 0.01$ ) and is greater than that obtained in areas with drusen associated atrophy (mean 16.4 dB; SD 0.9;  $p < 0.01$ )<sup>73</sup>. The area of drusen associated atrophy did not exhibit absolute loss as was the case in GA<sup>73</sup>.

Progression of GA can be monitored by fundus autofluorescence (FAF) as the areas of GA appear hypo-fluorescent. One study compared the outcome of MP-1 microperimetry to that from both near-infrared fundus autofluorescence (NIR-FAF) and short-wavelength FAF<sup>52</sup>. The associations between severe relative loss (a DLS of not more than 5 dB) and normal and hyper-fluorescence outcomes were determined for each FAF technique. It was concluded that the outcome from MP-1 microperimetry, in combination with both FAF techniques, allowed effective detection and monitoring of GA<sup>52</sup>. Another study used microperimetry to evaluate SD-OCT FAF and NIR-FAF<sup>20</sup>. As would be expected, DLS was substantially reduced in areas of GA, and the imaging techniques were able to detect the presence of GA with differing capabilities. SD-OCT was considered to be the most appropriate imaging technique to examine GA<sup>20</sup>.

#### *4. Outer retinal tubulations*

Outer retinal tubulations (ORTs) are not specific to AMD and are seen more commonly in inherited retinal disorders such as choroideremia and retinitis pigmentosa<sup>24</sup>. In AMD, they are not a typical feature and can occur in eyes with previous nAMD. The identification of ORTs is clinically important as they may be misinterpreted as either intraretinal or subretinal fluid, with the resultant unnecessary treatment<sup>33,79</sup>. In a study of individuals without ORTs who were treated for nAMD, the improvement in MS obtained with the MP-1 microperimeter after

12 months was less pronounced in those that developed ORTs (mean 6.31dB, SD 2.5) compared to those that did not (mean 9.89dB, SD 5.43;  $p < 0.01$ ). This study, however, did not fully describe the stimulus parameters for the microperimetry.

In summary, focal areas of reduced DLS in AMD can be identified by microperimetry and are associated with a disruption of the EZ band and/or changes to the RPE <sup>34,38,53,74</sup>. The association between reticular pseudodrusen and MS is equivocal. In early to intermediate AMD (AREDS 2, 3 and 4 <sup>7</sup>), the presence of pseudodrusen is associated with a reduction in MS at the macula; <sup>45</sup> however, there was no such association in a different cohort with intermediate AMD (Beckman classification<sup>19</sup>) <sup>75</sup>. The differences between areas with and without pseudodrusen, for early and intermediate AMD (Beckman classification <sup>19</sup>), combined, are seemingly most profound under scotopic conditions <sup>59</sup>. The reduction in MS is, in general, consistent with the presence of retinal lesions apparent by OCT. In the presence of a normal retinal appearance by fundus photography, microperimetry detects functional loss arising from nGA <sup>27,63,73</sup>.

#### D. Microperimetry and other measures of visual function.

Fifteen included studies used microperimetry alongside other measures of visual function in individuals with AMD <sup>3,5,11,18,23,30,43,45,48,49,56,69,71,72,77</sup>. In early AMD (International Classification and Grading System<sup>8</sup>) with distance VAs ranging from 20/20 to 20/40, the corresponding MS varied between 19.5dB (SD 0.4dB) and 14.9dB (SD 2.4dB) <sup>3</sup>. Similarly, in early to intermediate AMD (Beckman classification<sup>19</sup>) with a distance VA better than 20/40, MS exhibited a greater reduction compared to VA and to low luminance VA (LLVA) by 3.0 and 1.9 fold, respectively <sup>71</sup>. A prospective longitudinal study of intermediate AMD (Beckman classification<sup>19</sup>) <sup>72</sup>, compared two groups: those graded as progressed, defined as the development of additional



structural abnormality visible by colour fundus photography, and those graded as stable with unchanged features. No deterioration from baseline in either VA or LLVA was present in either group at 12 months; however, small but statistically significant reductions in group mean MS (obtained with the MAIA microperimeter) were present in both groups (mean 0.42dB; SE 0.12 and mean 0.31dB; SE 0.10, respectively) <sup>72</sup>. It should be noted, however, that microperimetry is only able to measure DLS to a resolution of 1dB, and therefore the clinical significance of these findings is limited. An additional finding of this latter study was that eyes identified as improved--defined as a disappearance of structural abnormality on color fundus photography--showed a statistically significant increase in the group mean MS (mean 1.13dB; SE 0.23,  $p<0.001$ ) at 12 months <sup>72</sup>. Another study that compared the outcomes in early AMD (AREDS grade 2 <sup>7</sup>) and in intermediate AMD (AREDS grade 3 <sup>7</sup>) to those in normal individuals found a significant worsening in LLVA for each AMD group ( $p<0.05$ ) <sup>11</sup>. The reduction in LLVA was associated with a reduction in foveal DLS ( $r^2=0.60$ ,  $p<0.01$ ) <sup>11</sup>. In early to intermediate AMD (AREDS grade 2 and 3 <sup>7</sup>), a reduction of parafoveal MS is associated with a reduction in VA and in contrast sensitivity (CS) ( $r=0.59$  and  $r=0.35$  respectively,  $p<0.01$ )<sup>45</sup>.

In a separate study of individuals with intermediate stage AMD (Beckman classification<sup>19</sup>), neither MS nor foveal DLS were associated with a low luminance deficit (LLD)--defined as the difference between VA and LLVA--or with the self-reported outcome to a 10-item night vision questionnaire. Nevertheless, LLD was significantly associated with difficulty under low luminance levels <sup>77</sup>.

In individuals with nAMD who had previously received anti-VEGF therapy, MS (out to 20° eccentricity) was moderately correlated with both VA ( $r=0.54$ ) and CS ( $r=0.53$ ) separately and, to a lesser extent, with reading speed ( $r=0.37$  all  $p<0.001$ ) <sup>56</sup>. In those undergoing anti-VEGF treatment, however, no association was present between the MS and either VA or CS <sup>30,43</sup>.

Other studies have shown that both DLS and VA improve up to either 6 months<sup>48</sup> or 12 months<sup>43</sup> of anti-VEGF therapy; however, the association between DLS and VA was not determined. In subfoveal CNV, an increase in the area of absolute DLS loss is associated with a decline in both reading acuity ( $r=0.52$ ;  $p=0.01$ ) and reading speed ( $r=-0.48$ ;  $p=0.02$ )<sup>18</sup>.

In GA manifesting absolute loss of DLS and a central island of residual vision (foveal sparing), the MS out to 20° eccentricity was moderately associated with reading speed ( $r^2=0.5$ )<sup>5</sup>. As an improvement in reading is a major goal of vision rehabilitation, microperimetry provides additional information about the location and size of the area(s) of residual function, allowing for a realistic estimation of reading ability and the likely outcome of rehabilitation<sup>5,23</sup>.

The multifocal electroretinogram (mfERG) provides objective, topographical, electrophysiological information about central retinal function. Two studies compared microperimetry and mfERG<sup>49,69</sup>. In early AMD (Wisconsin Age-related Maculopathy Grading system<sup>35</sup>), a significant correlation was present between the mfERG response amplitude density (N1-P1) and MS ( $r=0.69$ ,  $p<0.01$ )<sup>49</sup>; however, there was no association for intermediate AMD (Beckman classification<sup>19</sup>)<sup>69</sup>. This latter study found a greater reduction in the MS than in the mfERG ( $p<0.001$ ), suggesting that the two measures assess different aspects of retinal dysfunction<sup>69</sup>.

In summary, VA, CS and reading ability have historically been used as outcome measures in ophthalmic clinical research. Microperimetry has more recently become an additional outcome measure. MS exhibits a wide range of values in the presence of relatively good VA in early to intermediate AMD<sup>3</sup> (International Classification and Grading System<sup>8</sup>). It is able to detect progressive improvements in AMD, consistent with color fundus photographs, when no

change is observed in VA or LLVA. There is conflicting evidence as to the strength of the associations between DLS and VA, CS and reading ability <sup>43,71,72</sup>. Reading ability is an important factor when considering visual rehabilitation: microperimetry gives additional relevant information with respect to the area and location of residual function.

#### E. Microperimetry as an outcome measure in clinical trials of medical or surgical intervention

Microperimetry has been included as an outcome measure in 17 included articles describing clinical trials of medical and/ or surgical interventions for AMD. In individuals undergoing treatment with ranibizumab for AMD, MS, measured with the MAIA microperimeter, was at a maximum of 17dB for a central retinal thickness of 210 $\mu$ m. MS declined as the thickness increased, reaching a minimum of 7dB at a thickness of 320-339 $\mu$ m, and declined as the thickness decreased, reaching a minimum of 15dB at a thickness of <160 $\mu$ m <sup>4</sup>. These findings, however, cannot be compared with other studies as both the microperimetry and the method of measuring retinal thickness were not reported. A similar finding was noted with bevacizumab therapy: MS increased following a reduction in retinal thickness <sup>29</sup> and decreased with increasing retinal thickness ( $r=-0.54$ ,  $p<0.01$ ); <sup>55</sup> however, neither of these latter studies specified the thickness boundaries used in the retinal thickness measurements. It has been suggested that the improvement in MS occurs from the reduction in RPE lesion area with treatment rather than from a reduction in the retinal thickness, as a whole <sup>35</sup>.

The relationship between DLS and specific AMD morphology, as identified by SD-OCT, has been studied in previously untreated patients with nAMD who subsequently received aflibercept <sup>62</sup>. The greatest improvement in DLS (measured with the MP-1 microperimeter), occurred 3 months after the start of therapy; areas exhibiting a reduction in either a serous

PED or subretinal fluid exhibited the greatest improvement in group mean MS of 5.5dB and 4.0dB respectively ( $p < 0.001$ ). Areas with fibrovascular PED or with an intra-retinal cystoid space also improved, but to a lesser extent (group mean improvements 2.3dB and 1.7dB, respectively) <sup>62</sup>. In an earlier study, DLS improved following ranibizumab therapy in previously untreated patients with nAMD. The most marked improvement occurred at stimulus locations which were associated with a reduction in subretinal fluid, intraretinal fluid or intraretinal cystoid space <sup>60</sup>.

Although all trials of anti-VEGF therapy involving microperimetry report an improvement in DLS from baseline, the results of these studies are equivocal with respect to the duration of therapy beyond which the DLS ceases to improve. A number of studies have found that DLS continues to improve up until 12 months, the time at which the studies ended <sup>13,25,39,43,60</sup>; however, two studies suggest that DLS does not improve beyond that recorded after one week of treatment <sup>9,35</sup>. DLS can also decline following withdrawal of anti-VEGF therapy. Individuals with stable nAMD, who ceased anti-VEGF therapy, exhibited a reduction in DLS during the follow-up period (at least 3 visits over 7 months) when compared with those that continued to receive treatment <sup>4</sup>. It was speculated that the reduction in DLS may have resulted either from photoreceptor atrophy over time that was too subtle to be identified by VA or that CNV could be occurring at a subclinical level below that required by the United Kingdom NICE guidelines for an anti-VEGF injection <sup>4</sup>.

Two trials with unsuccessful outcomes utilized microperimetry as an outcome measure. One assessed the outcome of transpalpebral electrotherapy as a treatment for early to intermediate AMD (AREDS grade 2, 3 and 4<sup>7</sup>), and the other evaluated the outcome of photodynamic therapy combined with intravitreal triamcinolone as a treatment for nAMD <sup>6,17</sup>. Neither study found a sustained improvement in either DLS, VA, or CS, following treatment.

Macular translocation surgery (MT360) involves a peripheral retinectomy of 360° at the ora serata, following which the subfoveal CNV is removed and the whole retina is rotated such that the fovea is located away from the removed CNV. The retina is then reattached. In one study, distance VA, near VA, and reading speed improved post-operatively <sup>12</sup>. DLS was specified in terms of the median retinal sensitivity score (MRSS) obtained with the MP-1 microperimeter. The 12 month post-operative group mean MRSS was better (2.5dB, SD 4.3) in the foveal surgical area compared to the retinal area where the CNV had been removed (<0dB) <sup>12</sup>; however, the MRSS had not been evaluated prior to surgery; therefore it is not possible to evaluate whether the surgery improved visual function. Another study found that the MRSS only improved in lesions greater than 4 disc areas <sup>41</sup>; however, the two studies evaluated the outcome of the translocation surgery by differing methods. The first determined the MRSS at areas of healthy retina compared to that at the surgical sites <sup>12</sup>, whereas the second compared the difference in the MRSS for the pre- and 12-month post-operative areas <sup>41</sup>.

Two RCTs examined the effect of lutein supplementation on macular pigment optical density and the subsequent effect on visual function. One RCT found that, although lutein supplementation increased the macular pigment density, there was no improvement in MS after 6 months of lutein supplementation <sup>68</sup>. Macular pigment density was also weakly correlated with DLS ( $r = 0.25$ ,  $p = 0.027$ ) <sup>68</sup>. The second RCT examined differing levels of lutein supplementation (10mg, 20mg and a combination of lutein with zeaxanthin) with placebo. After two years of supplementation, the group mean MS, obtained with the MP-1 microperimeter, was greater for the groups receiving 10mg (13.37 dB) or 20 mg of lutein (12.55 dB) compared to the control group (10.32 dB,  $p < 0.05$ ) <sup>32</sup>.

It is clear that microperimetry has the ability to detect changes in visual function arising from a variety of interventions for AMD. All studies suggest that MS improves following anti-VEGF treatment as retinal thickness decreases and nAMD-associated lesions improve. The extent of any such improvement in MS beyond 12 months is unknown.

### **III. Discussion**

The quality of evidence varied among the 52 articles. Overall, none of the RCTs directly analysed the utility of microperimetry in the assessment of visual function in AMD but, as would be expected, evaluated a specific medical therapy using microperimetry as one of various outcome measures. Over half of the studies included in this review were observational in design and, therefore, have a consequent risk of selection bias, information bias, or confounding bias<sup>26</sup>. Many studies had limitations in the quality of reporting of the microperimetry outcomes and/or of the SD-OCT methods and analysis (Table 1). Comparison between studies was also confounded by the differences in the classification systems for early and intermediate AMD. Four studies did not include the classification method<sup>5,23,28,38</sup>. An additional difficulty in comparing studies arose from the differences in the dynamic range between the various microperimeters used in the studies.

The majority of studies used the summary statistic MS, which is not age-corrected, and many of the studies did not report either the number or the spatial location of the stimuli upon which the MS was based<sup>4,6,16,22,32,33,39,41,45,52</sup>. Only 12 of the studies analysed the DLS at each given stimulus location<sup>28,38,53,57,60–63,65,72–74</sup>. From the 52 included studies, two of the studies<sup>3,16</sup> utilised location-specific probability analysis of the measured DLS compared to the corresponding age-corrected normal value, as is conventional practice in SAP. Despite the

latter probability analysis enabling separation of focal from diffuse defects <sup>31</sup>, such an approach was not utilised in these two studies.

The absence of a robust statistical analysis software package for microperimetry that would separate focal from diffuse loss and that is comparable to that widely used in SAP currently limits the usefulness of the technique. Such analysis would enable a more clinically relevant evaluation of the microperimetry outcomes, particularly their association with structure. The various microperimeter manufacturers should be encouraged to develop such a package to allow this more comprehensive method of assessing abnormal visual function. In late stage AMD, this type of analysis would also need to be corrected for the presence for any retinal locus <sup>14</sup>.

The clinical value of microperimetry has not yet been assessed against other functional biomarkers of AMD, such as flicker sensitivity and dark adaptation, known to be sensitive to AMD disease severity <sup>15,47</sup> Microperimetry offers detailed topographical information relative to traditional measures of foveal function such as VA and CS. In addition, microperimetry was superior to VA in detection of subtle AMD changes in a longitudinal study over one year <sup>72</sup>. The investigation of microperimetry in comparison with dark adaptation in early AMD would be of value and enable clearer clinical recommendations for microperimetry.

Notwithstanding the above limitations, it is clear that there is a strong association between the magnitude of the DLS and a number of classic signs associated with AMD. Disruptions of the EZ band and RPE are associated with reduced DLS despite the maintenance of good VA <sup>29,34,38,49,74</sup>. OS thinning and RPE thickening are both associated with reduced MS, in early

AMD<sup>3</sup>. A thickening and a thinning of the whole retina in CNV are each associated with a reduced MS<sup>4,29,55</sup>.

#### **IV. Conclusion**

The current microperimetric literature is of varying quality, but has been improving in recent years. The current lack of consistency in the microperimetric techniques and in the analysis of DLS, limits the conclusions regarding the use of microperimetry in AMD. Recommendations for good clinical practice are, therefore, currently not possible; however, microperimetry provides information beyond that of VA and CS in the functional assessment of AMD. When combined with SD-OCT, it gives a multimodal representation of AMD morphology and associated visual function. Statistical analysis software similar to that used in SAP would render microperimetry a more robust procedure. The development of a multimodal topographical classification system for all stages of AMD based upon combined microperimetry and SD-OCT outcomes represents an exciting prospect.

#### **V. Methods of literature search**

The Medline, Ovid, EMBASE and Web of science databases were each searched using the search terms in Table 2. The search extended from 1950 (Medline only) to November 2016. The search terms were divided into two groups: population and instrument (Table 2). Each selected article was required to match at least one search term from each group. Additional articles were identified from the references within the publications identified by the primary search. The abstracts of articles found from the database search were independently assessed by two of the authors (NC and JA) to identify those that met the inclusion criteria.



Eligible articles had to include microperimetry undertaken on at least twenty eyes with AMD to provide a minimum level of evidence. All articles were required to contain the DLS outcome obtained by microperimetry. Preferred retinal location and fixation studies were excluded. Only articles that discussed microperimetry in the context of the outcome from other commercially available instrumentation were included. Conference abstracts and case reports were excluded. Studies where the whole article was not written in English were also excluded.

### **Funding sources**

Nicola Cassels is in receipt of a postgraduate research studentship from Cardiff University. Jennifer Acton was also in receipt of a grant by Fight for Sight [grant number 1463/64].

## VI. References

1. Acton JH, Bartlett NS, Greenstein VC. Comparing the Nidek MP-1 and Humphrey Field Analyzer in normal subjects. *Optom Vis Sci.* 2011;88(11):1288-1297.
2. Acton JH, Greenstein VC. Fundus-driven perimetry (microperimetry) compared to conventional static automated perimetry: similarities, differences, and clinical applications. *Can J Ophthalmol.* 2013;48(5):358-363.
3. Acton JH, Smith RT, Hood DC, Greenstein VC. Relationship between retinal layer thickness and the visual field in early age-related macular degeneration. *Investig Ophthalmol Vis Sci.* 2012;53(12):7618-7624.
4. Alexander P, Mushtaq F, Osmond C, Amoaku W. Microperimetric changes in neovascular age-related macular degeneration treated with ranibizumab. *Eye.* 2012;26(5):678-683.
5. Amore FM, Silvestri V, Turco S, De Rossi F, Cruciani F. Rehabilitative approach in patients with ring scotoma. *Can J Ophthalmol.* 2013;48(5):420-426.
6. Anastassiou G, Schneegans A-L, Selbach M, Kremmer S. Transpalpebral electrotherapy for dry age-related macular degeneration (AMD): an exploratory trial. *Restor Neurol Neurosci.* 2013;31(5):571-578.
7. AREDS. The Age-Related Eye Disease Study system for classifying age-related macular degeneration from stereoscopic color fundus photographs: the Age-Related Eye Disease Study Report Number 6. *Am J Ophthalmol.* 2001;132(5):668-681.
8. Bird AC, Bressler NM, Bressler SB, et al. An international classification and grading system for age-related maculopathy and age-related macular degeneration. The International ARM Epidemiological Study Group. *Surv Ophthalmol.* 1995;39(5):367-374.
9. Bolz M, Simader C, Ritter M, et al. Morphological and functional analysis of the loading regimen with intravitreal ranibizumab in neovascular age-related macular degeneration. *Br J Ophthalmol.* 2010;94(2):185-189.
10. Bunce C, Xing W, Wormald R. Causes of blind and partial sight certifications in England and Wales: April 2007-March 2008. *Eye.* 2010;24(11):1692-1699.
11. Chandramohan A, Stinnett SS, Petrowski JT, et al. Visual function measures in early and intermediate age-related macular degeneration. *Retina.* 2016;36(5):1021-1031.
12. Chieh J, Stinnett S, Toth C. Central and pericentral retinal sensitivity after macular translocation surgery. *Retina.* 2008;28(10):1522-1529.
13. Cho HJ, Kim CG, Yoo SJ, et al. Retinal functional changes measured by microperimetry in neovascular age-related macular degeneration treated with ranibizumab. *Am J Ophthalmol.* 2013;155(1):118-126.e1.
14. Denniss J, Astle AT. Spatial interpolation enables normative data comparison in gaze-contingent microperimetry. *Investig Ophthalmol Vis Sci.* 2016;57(13):5449-5456.
15. Dimitrov PN, Robman LD, Varsamidis M, et al. Visual function tests as potential biomarkers in age-related macular degeneration. *Investig Ophthalmology Vis Sci.* 2011;52(13):9457.
16. Dinc UA, Yenerel NM, Gorgun E, Oncel M. Assessment of macular function by microperimetry in intermediate age-related macular degeneration. *Eur J Ophthalmol.* 2008;18(4):595-600.
17. Dunavoelgyi R, Sacu S, Simader C, Prunte C, Schmidt-Erfurth U. Changes in

- macular sensitivity after reduced fluence photodynamic therapy combined with intravitreal triamcinolone. *Acta Ophthalmol.* 2011;89(2):166-171.
18. Ergun E, Maár N, Radner W, Barbazetto I, Schmidt-Erfurth U, Stur M. Scotoma size and reading speed in patients with subfoveal occult choroidal neovascularization in age-related macular degeneration. *Ophthalmology.* 2003;110(1):65-69.
  19. Ferris FL, Wilkinson CP, Bird A, et al. Clinical classification of age-related macular degeneration. *Ophthalmology.* 2013;120(4):844-851.
  20. Forte R, Querques G, Querques L, Leveziel N, Benhamou N, Souied EH. Multimodal evaluation of foveal sparing in patients with geographic atrophy due to age-related macular degeneration. *Retina.* 2013;33(3):482-489.
  21. Forte R, Querques G, Querques L, Massamba N, Le Tien V, Souied EH. Multimodal imaging of dry age-related macular degeneration. *Acta Ophthalmol.* 2012;90(4):e281-7.
  22. Fujii GY, De Juan E, Humayun MS, Sunness JS, Chang TS, Rossi J V. Characteristics of visual loss by scanning laser ophthalmoscope microperimetry in eyes with subfoveal choroidal neovascularization secondary to age-related macular degeneration. *Am J Ophthalmol.* 2003;136(6):1067-1078.
  23. Giacomelli G, Virgili G, Giansanti F, et al. Clinical and microperimetric predictors of reading speed in low vision patients: a structural equation modeling approach. *Investig Ophthalmol Vis Sci.* 2013;54(6):4403-4408.
  24. Goldberg NR, Greenberg JP, Laud K, Tsang S, Freund KB. Outer retinal tubulation in degenerative retinal disorders. *Retina.* 2013;33(9):1871-1876. doi:10.1097/IAE.0b013e318296b12f.
  25. Grenga PL, Fragiotta S, Meduri A, Lupo S, Marengo M, Vingolo EM. Fixation stability measurements in patients with neovascular age-related macular degeneration treated with ranibizumab. *Can J Ophthalmol.* 2013;48(5):394-399.
  26. Grimes D, Schulz K. Bias and causal associations in observational research. *Lancet.* 2002;359:248-252.
  27. Hariri AH, Tepelus TC, Akil H, Nittala MG, Sadda SR. Retinal sensitivity at the junctional zone of eyes with geographic atrophy due to age-related macular degeneration. *Am J Ophthalmol.* 2016;168:122-128.
  28. Hartmann KI, Bartsch D-UG, Cheng L, et al. Scanning laser ophthalmoscope imaging stabilized microperimetry in dry age-related macular degeneration. *Retina.* 2011;31(7):1323-1331.
  29. Hartmann KI, Oster SF, Amini P, Bartsch D-U, Cheng L, Freeman WR. SLO-microperimetry in wet age-related macular degeneration during anti-VEGF therapy. *Ophthalmic Surgery, Lasers Imaging Retin.* 2015;46(8):824-830.
  30. Hautamäki A, Oikkonen J, Onkamo P, Immonen I. Correlation between components of newly diagnosed exudative age-related macular degeneration lesion and focal retinal sensitivity. *Acta Ophthalmol.* 2014;92(1):51-58.
  31. Heijl A, Lindgren G, Olsson J. A package for the statistical analysis of visual fields. In: Greve EL, Heijl A, eds. *Seventh International Visual Field Symposium, Amsterdam, September 1986.* Vol 49. Documenta Ophthalmologica Proceedings Series. Amsterdam: Martinus Nijhodd Publishers/Dr W. Junk Publishers; 1987:153-168.
  32. Huang Y-M, Dou H-L, Huang F-F, et al. Changes following supplementation with lutein and zeaxanthin in retinal function in eyes with early age-related macular

- degeneration: a randomised, double-blind, placebo-controlled trial. *Br J Ophthalmol*. 2015;99(3):371-375.
33. Iaculli C, Barone A, Scudieri M, Palimbo M, Giovanna. Outer retinal tubulation: Characteristics in patients with neovascular age-related macular degeneration. *Retina*. 2015;35(10):1979-1984.
  34. Iwama D, Tsujikawa A, Ojima Y, et al. Relationship between retinal sensitivity and morphologic changes in eyes with confluent soft drusen. *Clin Experiment Ophthalmol*. 2010;38(5):483-488.
  35. Kiss CG, Geitzenauer W, Simader C, Gregori G, Schmidt-Erfurth U. Evaluation of ranibizumab-induced changes in high-resolution optical coherence tomographic retinal morphology and their impact on visual function. *Investig Ophthalmol Vis Sci*. 2009;50(5):2376-2383.
  36. Klein R, Davis MD, Magli YL, Segal P, Klein BE, Hubbard L. The Wisconsin age-related maculopathy grading system. *Ophthalmology*. 1991;98(7):1128-1134.
  37. Klein R, Lee KE, Gangnon RE, Klein BEK. Incidence of visual impairment over a 20-year period: the Beaver Dam Eye Study. *Ophthalmology*. 2013;120(6):1210-1219.
  38. Landa G, Su E, Garcia PMT, Seiple WH, Rosen RB. Inner segment-outer segment junctional layer integrity and corresponding retinal sensitivity in dry and wet forms of age-related macular degeneration. *Retina*. 2011;31(2):364-370.
  39. Lazzeri S, Figus M, Sartini MS, et al. Intravitreal ranibizumab for predominantly hemorrhagic choroidal neovascularization in age-related macular degeneration. *Ophthalmologica*. 2015;233(2):74-81.
  40. Markowitz SN, Reyes S V. Microperimetry and clinical practice: an evidence-based review. *Can J Ophthalmol*. 2013;48(5):350-357.
  41. Mettu PS, Sarin N, Stinnett SS, Toth CA. Recovery of the neurosensory retina after macular translocation surgery is independent of preoperative macular sensitivity in neovascular age-related macular degeneration. *Retina*. 2011;31(8):1637-1649.
  42. Midená E, Vujosevic S, Convento E, Manfre' A, Cavarzeran F, Pilotto E. Microperimetry and fundus autofluorescence in patients with early age-related macular degeneration. *Br J Ophthalmol*. 2007;91(11):1499-1503.
  43. Munk MR, Kiss C, Huf W, et al. One year follow-up of functional recovery in neovascular AMD during monthly anti-VEGF treatment. *Am J Ophthalmol*. 2013;156(4):633-643.
  44. Neelam K, Nolan J, Chakravarthy U, Beatty S. Psychophysical function in age-related maculopathy. *Surv Ophthalmol*. 2009;54(2):167-210.
  45. Ooto S, Suzuki M, Vongkulsiri S, Sato T, Spaide R. Multimodal visual function testing in eyes with nonexudative age-related macular degeneration. *Retina*. 2015;35(9):1726-1734.
  46. Owsley C, Jackson GR, White M, Feist R, Edwards D. Delays in rod-mediated dark adaptation in early age-related maculopathy. *Ophthalmology*. 2001;108(7):1196-1202.
  47. Owsley C, McGwin G, Jackson GR, Kallies K, Clark M. Cone- and rod-mediated dark adaptation impairment in age-related maculopathy. *Ophthalmology*. 2007;114(9):1728-1735.
  48. Ozdemir H, Karacorlu M, Senturk F, Karacorlu SA, Uysal O. Microperimetric changes after intravitreal bevacizumab injection for exudative age-related macular degeneration. *Acta Ophthalmol*. 2012;90(1):71-75.

49. Parisi V, Perillo L, Tedeschi M, et al. Macular function in eyes with early age-related macular degeneration with or without contralateral late age-related macular degeneration. *Retina*. 2007;27(7):879-890.
50. Parravano M, Oddone F, Tedeschi M, et al. Retinal functional changes measured by microperimetry in neovascular age-related macular degeneration treated with ranibizumab: 24-month results. *Retina*. 2010;30(7):1017-1024.
51. Pilotto E, Convento E, Guidolin F, et al. Microperimetry features of geographic atrophy identified with en face optical coherence tomography. *JAMA Ophthalmol*. 2016;134(8):873.
52. Pilotto E, Vujosevic S, Melis R, et al. Short wavelength fundus autofluorescence versus near-infrared fundus autofluorescence, with microperimetric correspondence, in patients with geographic atrophy due to age-related macular degeneration. *Br J Ophthalmol*. 2011;95(8):1140-1144.
53. Querques L, Querques G, Forte R, Souied EH. Microperimetric correlations of autofluorescence and optical coherence tomography imaging in dry age-related macular degeneration. *Am J Ophthalmol*. 2012;153(6):1110-1115.
54. Resnikoff S, Pascolini D, Etya'ale D, et al. Global data on visual impairment in the year 2002. *Bull World Health Organ*. 2004;82(11):844-851.
55. Sabour-Pickett S, Loughman J, Nolan JM, et al. Visual performance in patients with neovascular age-related macular degeneration undergoing treatment with intravitreal ranibizumab. *J Ophthalmol*. 2013;2013:268438.
56. Sato T, Suzuki M, Ooto S, Spaide R. Multimodal imaging findings and multimodal vision testing in neovascular age-related macular degeneration. *Retina*. 2015;35(7):1292,1302.
57. Sayegh RG, Kiss CG, Simader C, et al. A systematic correlation of morphology and function using spectral domain optical coherence tomography and microperimetry in patients with geographic atrophy. *Br J Ophthalmol*. 2014;98(8):1050-1055. doi:10.1136/bjophthalmol-2014-305195.
58. Sohrab MA, Smith RT, Salehi-Had H, Sadda SR, Fawzi AA. Image registration and multimodal imaging of reticular pseudodrusen. *Investig Ophthalmol Vis Sci*. 2011;52(8):5743-5748.
59. Steinberg JS, Saßmannshausen M, Fleckenstein M, et al. Correlation of partial outer retinal thickness with scotopic and mesopic fundus-controlled perimetry in patients with reticular drusen. *Am J Ophthalmol*. 2016;168:52-61.
60. Sulzbacher F, Kiss C, Kaider A, et al. Correlation of OCT characteristics and retinal sensitivity in neovascular age-related macular degeneration in the course of monthly ranibizumab treatment. *Investig Ophthalmol Vis Sci*. 2013;54(2):1310-1315.
61. Sulzbacher F, Kiss C, Kaider A, et al. Correlation of SD-OCT features and retinal sensitivity in neovascular age-related macular degeneration. *Investig Ophthalmol Vis Sci*. 2012;53(10):6448-6455.
62. Sulzbacher F, Roberts P, Munk MR, et al. Relationship of retinal morphology and retinal sensitivity in the treatment of neovascular age-related macular degeneration using aflibercept. *Investig Ophthalmol Vis Sci*. 2015;56(2):1158-1167.
63. Takahashi A, Ooto S, Yamashiro K, et al. Photoreceptor damage and reduction of retinal sensitivity surrounding geographic atrophy in age-related macular degeneration. *Am J Ophthalmol*. 2016;168:260-268.

64. Tao LW, Wu Z, Guymer RH, Luu CD. Ellipsoid zone on optical coherence tomography: a review. *Clin Exp Ophthalmol*. 2016;44(5):422-430.
65. Vujosevic S, Smolek MK, Lebow KA, Notaroberto N, Pallikaris A, Casciano M. Detection of macular function changes in early (AREDS 2) and intermediate (AREDS 3) age-related macular degeneration. *Ophthalmologica*. 2011;225(3):155-160.
66. W.H.O. Priority eye diseases.
67. Webb RH, Hughes GW. Scanning laser ophthalmoscope. *IEEE Trans Biomed Eng*. 1981;28(7):488-492.
68. Weigert G, Kaya S, Pemp B, et al. Effects of lutein supplementation on macular pigment optical density and visual acuity in patients with age-related macular degeneration. In: *Macular Carotenoids Conference 2013*. Vol 52. Cambridge, UK: European Journal of Ophthalmology; 2013:23 (4) (pp.605).
69. Wu Z, Ayton LN, Guymer RH, Luu CD. Comparison between multifocal electroretinography and microperimetry in age-related macular degeneration. *Investig Ophthalmol Vis Sci*. 2014;55(10):6431-6439.
70. Wu Z, Ayton LN, Guymer RH, Luu CD. Intrasession test-retest variability of microperimetry in age-related macular degeneration. *Investig Ophthalmol Vis Sci*. 2013;54(12):7378-7385.
71. Wu Z, Ayton LN, Guymer RH, Luu CD. Low-luminance visual acuity and microperimetry in age-related macular degeneration. *Ophthalmology*. 2014;121(8):1612-1619.
72. Wu Z, Ayton LN, Luu CD, Guymer RH. Longitudinal changes in microperimetry and low luminance visual acuity in age-related macular degeneration. *JAMA Ophthalmol*. 2015;133(4):442-448.
73. Wu Z, Ayton LN, Luu CD, Guymer RH. Microperimetry of nascent geographic atrophy in age-related macular degeneration. *Investig Ophthalmol Vis Sci*. 2015;56(1):115-121.
74. Wu Z, Ayton LN, Luu CD, Guymer RH. Relationship between retinal microstructures on optical coherence tomography and microperimetry in age-related macular degeneration. *Ophthalmology*. 2014;121(7):1445-1452.
75. Wu Z, Ayton LN, Makeyeva G, Guymer RH, Luu CD. Impact of reticular pseudodrusen on microperimetry and multifocal electroretinography in intermediate age-related macular degeneration. *Investig Ophthalmol Vis Sci*. 2015;56(3):2100-2106.
76. Wu Z, Cunefare D, Chiu E, et al. Longitudinal associations between microstructural changes and microperimetry in the early stages of age-related macular degeneration. *Investig Ophthalmol Vis Sci*. 2016;57(8):3714.
77. Wu Z, Guymer RH, Finger RP. Low luminance deficit and night vision symptoms in intermediate age-related macular degeneration. *Br J Ophthalmol*. 2016;100(3):395-398.
78. Wu Z, Luu CD, Ayton LN, et al. Optical coherence tomography-defined changes preceding the development of drusen-associated atrophy in age-related macular degeneration. *Ophthalmology*. 2014;121(12):2415-2422.
79. Zweifel SA, Engelbert M, Laud K, et al. Outer retinal tubulation. *Arch Ophthalmol*. 2009;127(12):1596.
80. Zweifel SA, Spaide RF, Curcio CA, Malek G, Imamura Y. Reticular pseudodrusen are

subretinal drusenoid deposits. *Ophthalmology*. 2010;117(2):303-12.e1.

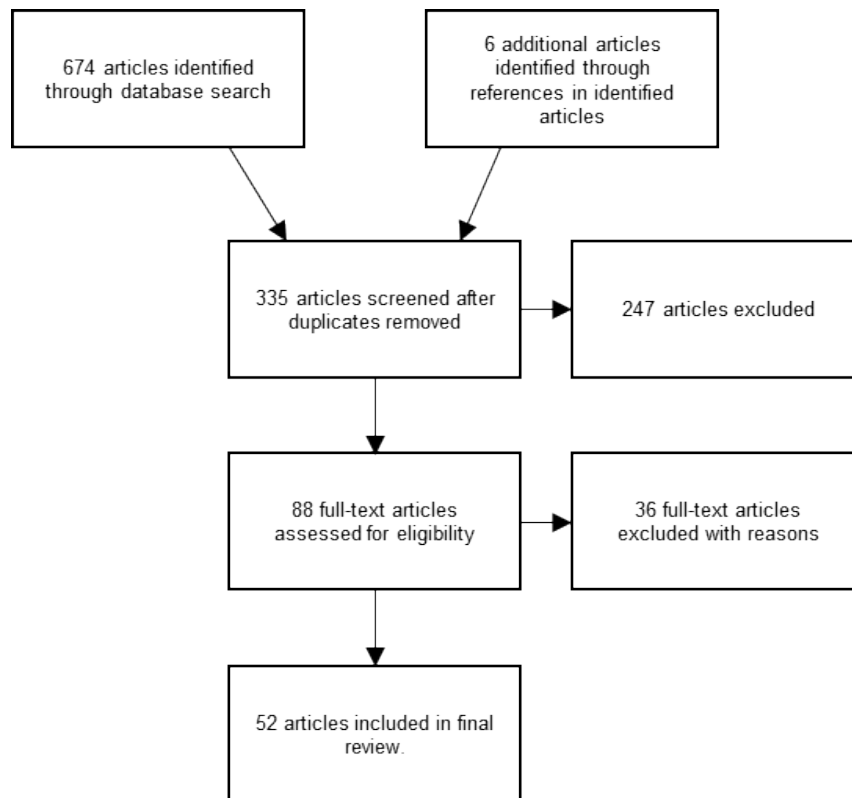


Figure 1. A Flow diagram demonstrating the primary identified articles and those included and excluded at each stage of the literature review. Adapted from PRISMA (Preferred Reporting Items for Systematic Reviews and Meta-Analysis).



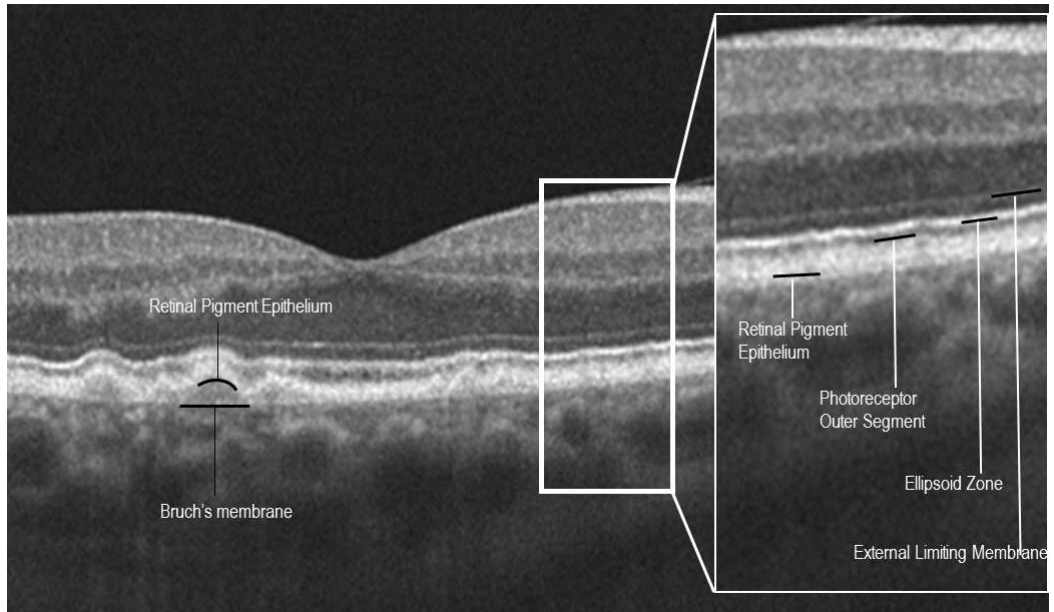


Figure 2. SD-OCT horizontal line scan of an eye with AMD. Right: The external limiting membrane, ellipsoid zone, photoreceptor outer segment and retinal pigment epithelium are highlighted by the three black lines which are continuous with the respective layers. Left: The separation of the RPE from Bruch's membrane due to drusen.

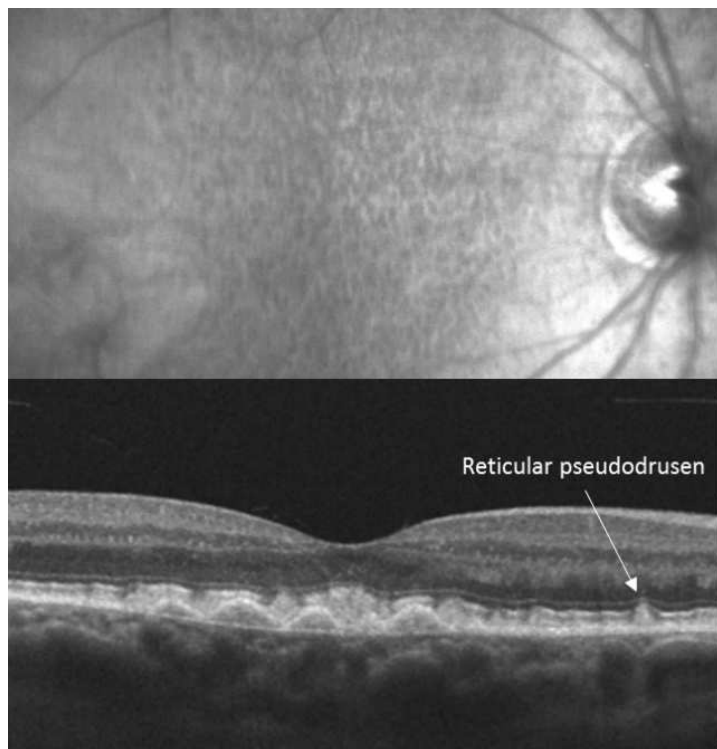


Figure 3. Top: Infra-red image and Bottom: SD-OCT horizontal line scan of an eye with AMD exhibiting a reticular pseudodrusen.

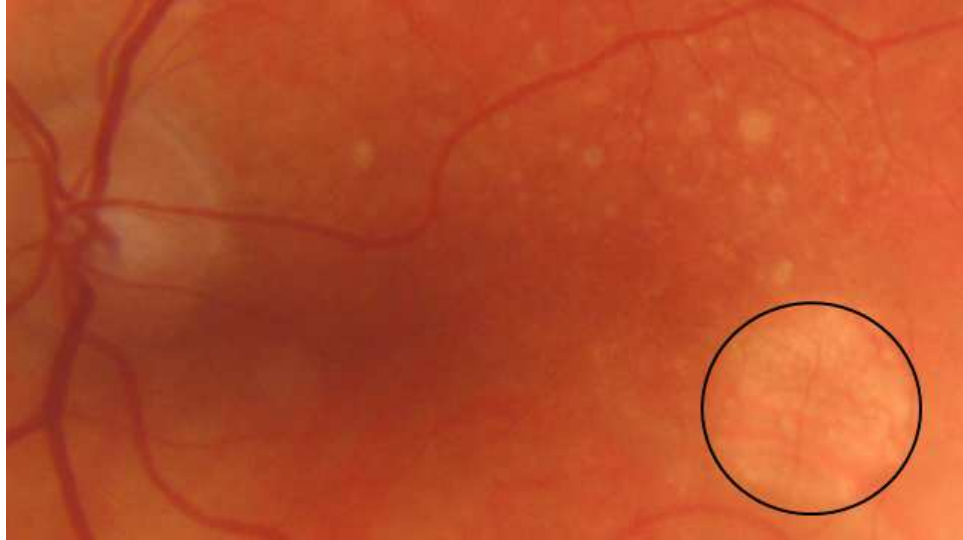


Figure 4. Colour fundus photograph of an eye with AMD exhibiting drusen and an area of GA (circled) with visible choroidal vessels.

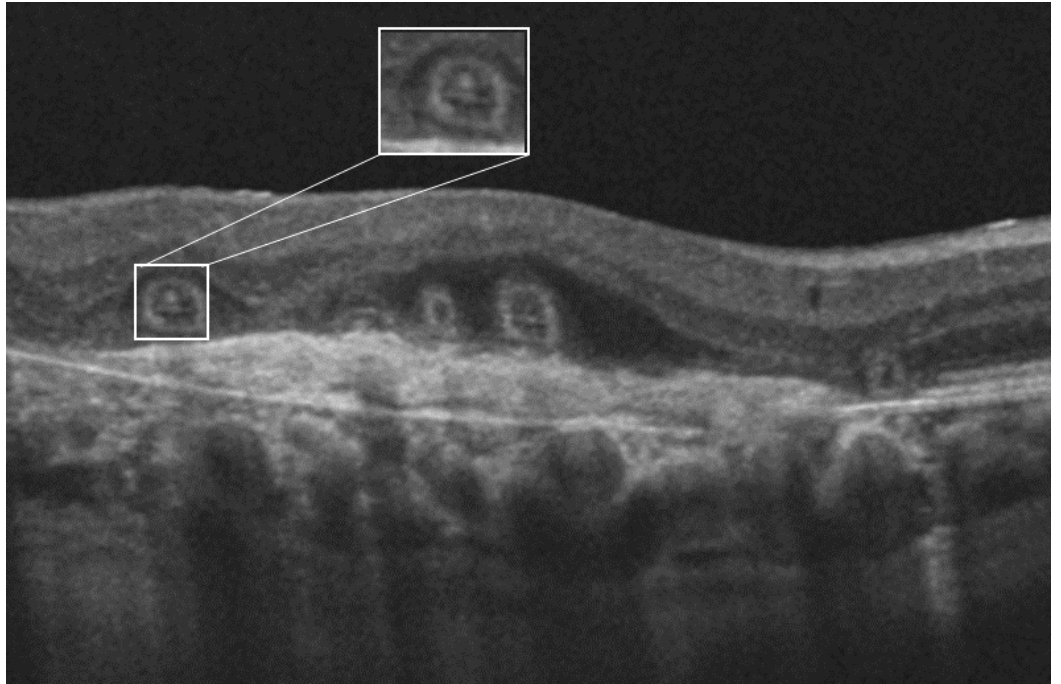


Figure 5. SD-OCT horizontal line scan of an eye with AMD exhibiting outer retinal tubulations (highlighted).

Reference	Author and year	Study design	AMD identification and classification	DLS measures used	Quality of evidence
3	Acton et al, 2012	Observational: case-controlled	Early AMD: International Classification and Grading System	MS (68 locations within 10°), number of TD defects, MD and PSD (derived from previous normative data)	High
11	Chandramohan et al, 2016	Observational: case-controlled	Early and intermediate AMD: AREDS classification (grades 2 and 3)	MS (37 locations within 5°), central MS (foveal locus and 12 locations at 1°) and percentage reduced threshold (under 25dB)	High
18	Ergun et al, 2003	Observational: case series	nAMD: identified by FA	Size of absolute and relative scotoma	High
20	Forte et al, 2013	Observational: case series	GA: identified with colour fundus photography	MS (49 locations within 3.5°), Dense scotoma (0dB) and relatively dense scotoma (<5dB)	High
27	Hariri et al, 2016	Observational: cross-sectional	Early to late AMD (GA): identified and classified by OCT (presence of drusen = intermediate, GA larger than 0.1 = GA)	MS (in different zones associated with GA)	High
34	Iwama et al, 2010	Observational: case series	Soft confluent drusen: International Classification and Grading System	MS (57 locations over 10°, in central 2° and at specific locations with pathomorphology)	High
43	Munk et al, 2013	Experimental: Quasi-experiment (interrupted time-series)	nAMD: naïve to treatment, identified with FA	MS (ETDRS grid areas), Number of absolute scotoma (0dB), severe relative scotoma (1-6dB), mild relative scotoma (7-12dB) and normal (>13dB) were counted.	High
48	Ozdemir et al, 2012	Experimental: Quasi-experiment (interrupted time-series)	nAMD: identified with FA and OCT	MS (12 locations within 4°) and number of absolute scotoma (0dB) from all 76 stimulus locations within 20°	High
49	Parisi et al, 2007	Observational: case-controlled	Early AMD: classified by Wisconsin Age-related Maculopathy Grading System	Central MS (4 locations within 2.5°) and paracentral MS (28 locations in annuli between 2.5 and 5°)	High
53	Querques et al, 2012	Observational: cross-sectional	Early to late AMD (GA): presence of soft indistinct drusen with RPE changes, and/or GA, identified with colour fundus photography	MS (49 locations within 4.5°), pointwise DLS (at specific locations with pathomorphology)	High
56	Sato et al, 2015	Observational: cross-sectional	nAMD: identified by OCT and FA	MS and Median DLS (29 locations within 10°)	High

57	Sayegh et al, 2014	Observational: case series	GA: identified by fundus examination	Pointwise DLS (at specific locations with pathomorphology)	High
62	Sulzbacher et al, 2015	Experimental, Quasi-experiment (interrupted time-series)	nAMD: naïve to treatment, identified with FA	MS (33 locations within 6°), pointwise DLS (at specific locations with pathomorphology)	High
65	Vujosevic et al, 2011	Observational: case-controlled	Early to intermediate AMD: AREDS classification (stage 2 to 3)	MS (61 locations within 5°), K value: total number of locations <24dB, pointwise DLS	High
68	Weigert et al, 2013	Experimental, RCT	Early to late AMD (GA): AREDS classification (stage 2, 3, and 4)	MS (41 locations within 6°)	High
70	Wu et al, 2013	Observational: case-controlled	Intermediate AMD: Beckman classification	MS (37 locations within 6°), pointwise DLS	High
74	Wu et al, 2014a	Observational: cross-sectional	Intermediate AMD: Beckman classification	Pointwise DLS (at specific locations with pathomorphology) and Z score (average of 2 examinations in relation to normative data)	High
69	Wu et al, 2014b	Observational: case-controlled	Intermediate AMD: Beckman classification	MS (corresponding to mfERG hexagons)	High
71	Wu et al, 2014c	Observational: cross-sectional	Intermediate AMD: Beckman classification	MS (5 locations within central 1°)	High
73	Wu et al, 2015a	Observational: cross-sectional	Intermediate AMD: Beckman classification	MS (associated with groups of AMD pathology severity) and pointwise DLS (at specific locations with pathomorphology)	High
72	Wu et al, 2015b	Observational: longitudinal case-controlled	Intermediate AMD: Beckman classification	MS (37 locations within 6°) and pointwise DLS	High
75	Wu et al, 2015c	Observational: cross-sectional	Intermediate AMD: Beckman classification	MS (25 locations within 4°)	High
76	Wu et al, 2016a	Observational: longitudinal case series	Intermediate AMD: Beckman classification	MS (37 locations within 6°), MS within EDTRS grid sections	High
77	Wu et al, 2016b	Observational: cross-sectional	Intermediate AMD: Beckman classification	MS (37 locations within 6°) and central MS (5 locations within 1°)	High
5	Amore et al, 2013	Observational: case series	AMD: with absolute scotoma and central fixation identified by microperimetry	Global MS and central MS. Size (in degrees) of central spared area (ring scotoma patients).	Medium 'central vision area' DLS definition not reported AMD: not stated method AMD is classified
9	Bolz et al, 2010	Experimental: Quasi-experiment (interrupted time-series)	nAMD: naïve to treatment	MS (foveal locus and circle of locations at 3.5°)	Medium OCT: boundaries used to define central retinal thickness not reported AMD: method nAMD is identified not stated

12	Chieh et al, 2008	Experimental: Quasi-experiment	nAMD	Median DLS within surgery areas and number of areas with absolute scotoma (<0dB)	Medium AMD: method nAMD is identified not stated
13	Cho et al, 2013	Experimental: Quasi-experiment (interrupted time-series)	nAMD: naïve to treatment, identified by FA and/or OCT	MS (28 locations within 6°)	Medium OCT: boundaries used to define central retinal thickness not reported
17	Dunavoelgyi et al, 2011	Experimental: RCT	nAMD: naïve to treatment	MS (41 locations within 6°), number of locations and size of absolute scotoma (0dB) and relative scotoma (<10dB)	Medium AMD: method nAMD is identified not stated
22	Fujii et al, 2003	Observational: cross-sectional	nAMD: identified by FA	Percentage presence of dense central scotoma (defined as having >3 locations of <0dB within 1.5°)	Medium Microperimetry: stimulus location pattern and stimulus details not reported
25	Grenga et al, 2013	Experimental: Quasi-experiment (interrupted time-series)	nAMD: naïve to treatment	MS (45 locations over 10°), number of absolute scotoma locations	Medium Microperimetry: Absolute scotoma definition not reported AMD: method nAMD is identified not stated
29	Hartmann et al, 2015	Experimental: Quasi-experiment (interrupted time-series)	nAMD: presence of $\square$ 250 $\mu$ m retinal thickness, subretinal fluid or PED.	MS (24 locations within 10°)	Medium OCT: boundaries used to define retinal thickness not reported
32	Huang et al, 2015	Experimental: RCT	Early AMD: AREDS classification (grade 2)	MS (average DLS at 1, 3 and 5° from fixation)	Medium Microperimetry: stimulus pattern not reported
35	Kiss et al, 2009	Experimental: Quasi-experiment (interrupted time-series)	nAMD: identified with FA	MS (25 stimulus locations within 7.9°), central 0°, paracentral 3.5° and eccentric 7.9° MS and absolute scotoma size.	Medium Microperimetry: absolute scotoma definition and mode of analysis not reported
38	Landa et al, 2011	Observational: cross-sectional	Early to late AMD (GA): drusen or atrophic changes, and nAMD: CNV, intra/subretinal fluid and haemorrhages	MS (28 locations), pointwise DLS	Medium Microperimetry: Stimulus degrees not reported AMD: method AMD is identified or classified not stated
41	Mettu et al, 2011	Experimental: Quasi-experiment (interrupted time-series)	nAMD: identified with FA	Median DLS (30 locations) and percentage non response (<0dB).	Medium Microperimetry: stimulus degrees not reported
45	Ooto et al, 2015	Observational: cross-sectional	Early to late AMD (GA): AREDS classification (2,3, or 4)	MS (29 locations within 20° and parafovea: central 9 locations)	Medium Microperimetry: how stimulus pattern not reported
52	Pilotto et al, 2016	Observational: case series	GA: identified from fundus examination	MS and number of locations with relatively dense scotoma ( $\leq$ 5dB)	Medium Microperimetry: stimulus pattern and degrees not reported

51	Pilotto et al, 2011	Observational: cross-sectional	GA: identified from fundus examination	MS (customised grid within 8° including all areas of GA), divided into 3 groups based on MS, relative and dense scotoma rate	Medium Microperimetry: relative scotoma definition not reported
55	Sabour-Pickett et al, 2013	Experimental: Quasi-experiment (interrupted time-series)	nAMD: identified with FA	MS (fixation, central 5° and all 21 locations within 16°)	Medium OCT: retinal boundaries used were 'thickness between outer most boundaries of scan' however, these are not specified.
59	Steinberg et al, 2016	Observational: case-controlled	Early or intermediate AMD with reticular pseudodrusen: Beckman classification and IR images	MS (56 locations) of areas with RPD compared to areas without (scotopic and mesopic)	Medium Microperimetry: stimulus degrees not reported
61	Sulzbacher et al, 2012	Observational: case series	nAMD: identified with colour fundus photography, OCT and FA	MS (33 locations within 6°), pointwise DLS (at specific locations with pathomorphology)	Medium Microperimetry: 'central retinal sensitivity' definition not reported
60	Sulzbacher et al, 2013	Experimental, Quasi-experiment (interrupted time-series)	nAMD: naïve to treatment, identified with colour fundus photography, OCT and FA	MS (33 locations within 6°), pointwise DLS (at specific locations with pathomorphology)	Medium OCT: pathomorphology used within analysis not defined and method of identification not reported
63	Takahashi et al, 2016	Observational: cross-sectional	GA: identified by fundus examination	MS (57 locations within 10° and over specific areas of retinal damage)	Medium Microperimetry: stimulus pattern not reported
23	Giacomelli et al, 2013	Observational: cross-sectional	Advanced AMD	MS (19 locations over 10°)	Medium: AMD: method AMD is identified or classified not stated
28	Hartmann et al, 2011	Observational: case-controlled	Early to late AMD (GA): presence of drusen on fundus examination	Ranked DLS threshold values and MS (28 locations within 10°), pointwise DLS overlying drusen	Medium: AMD: method AMD is classified not stated
30	Hautamaki et al, 2014	Observational: cross-sectional	nAMD: naïve to treatment	MS and ranking order of DLS (28 locations within 7.5°)	Medium: AMD: method AMD is identified not stated
4	Alexander et al, 2012	Experimental: Quasi-experiment (interrupted time-series)	nAMD: enrolled from anti-VEGF clinic	MS, macular integrity index (MAIA software)	Poor Confusing terminology (stable and unstable used to refer to both fixation and AMD status) Microperimetry: stimulus pattern, number of locations, algorithm and stimulus details not reported OCT: scan details not included and boundaries used to define retinal thickness not reported AMD: how nAMD is identified not stated
6	Anastassiou et al, 2013	Experimental: RCT	Early to late AMD (GA): AREDS classification (grades 2,3 and 4)	MS (37 locations within 10°)	Poor Microperimetry: stimulus pattern, algorithm and stimulus details not defined



					OCT: scan details not included and method of measuring retinal and choroidal thickness not reported
16	Dinc et al, 2008	Observational: case-controlled	Intermediate AMD: AREDS classification (grade 3)	MS (76 locations within 10°) and mean defect.	Poor Microperimetry: Mean defect derivation not reported, assumed it is from MP-1 software, stimulus pattern not reported OCT: scan details not included and boundaries used to define central retinal thickness not reported
33	Iaculli et al, 2015	Experimental: Quasi-experiment (interrupted time-series)	nAMD: identified by OCT and FA	MS (8°)	Poor Microperimetry: stimulus pattern and details not defined OCT: scan details not included and boundaries used to define central retinal thickness not reported
39	Lazzeri et al, 2015	Experimental: Quasi-experiment (interrupted time-series)	nAMD: identified with FA	MS (33 locations within 6°)	Poor Confusing terminology: both 'mean central retinal sensitivity' and 'mean retinal sensitivity' used; and 'Central retinal thickness' and 'central macular thickness' both used. Difference in terms not reported. Microperimetry: stimulus pattern and details not reported OCT: scan details not included and boundaries used to define central retinal thickness not reported

Table 1. Quality of evidence of the 52 included articles. AMD: age-related macular degeneration; AREDS: Age-related Eye Disease Study; DLS: differential light sensitivity; ETDRS: Early Treatment Diabetic Retinopathy Study; FA: fluorescein angiography; GA: geographic atrophy; MD: Mean Deviation; MS: Mean Sensitivity; nAMD: neovascular AMD; OCT: Optical coherence tomography; PSD: Pattern Standard Deviation; TD: Total Deviation.

Population		Instrument
Age-related Macul*	AND	Microperimet*
AMD		Fundus controlled perimet*
ARMD		
Macular degeneration		
Dry Macular degeneration		
Wet Macular degeneration		
Senile Macular degeneration		

Table 2. Terms used in the database search (\*=truncation: includes various word endings into search).